17 DISORDERS OF THE DEVELOPING NERVOUS SYSTEM

Overview

Amazing events in growth and development occur before birth as one cell develops into an infant. In spite of the immense complexity, most infants are born with a normal nervous system containing 50 to 100 billion functioning nerve cells. Unfortunately, 1% to 2% of infants are born with neurodevelopmental defects. About 40% of deaths in the first year of life are related to malformations of the CNS and an unknown percent of spontaneous deaths in utero result from CNS maldevelopment. Although the cause of neurodevelopmental defects is unknown in 60%, defects can occur from several causes, including genetic mutations, exposure to toxins or teratogens, CNS infections, metabolic deficiencies, and trauma. Table 17-1 lists some of the more commonly recognized causes.

Equally important as the cause of the CNS insult is the timing. By 3 weeks' gestation, the primitive neural tube has begun to develop and CNS growth and maturation continue throughout the embryonic period (0–8 weeks), the fetal period (9–38 weeks), infancy, and well into late childhood. The characteristics of the malformation depend on the timing of the CNS developmental disruption, although some insults, such as genetic mutations, may disrupt development over extended periods, causing a variety of defects. In addition, multiple abnormalities may occur from a single primary deficit in early morphogenesis, causing a cascading process of secondary and tertiary errors in morphogenesis. Insults that affect the CNS from weeks 3 to 6 usually produce major morphologic abnormalities while insults occurring later may produce more subtle or localized dysfunction. Thus it is possible to determine the latest time in gestation a malformation could occur but not the earliest. Table 17-2 presents the gestational timing of some neurodevelopmental milestones.

Based on a limited number of fetuses studied by anatomists and experimental studies of vertebrates and invertebrates, we are gaining a glimpse of the incredibly complex sequence of events that must occur at precise times for normal brain development. The basic steps of development are neurulation, neuronal and glial proliferation, migration, differentiation of neurons with axonal, dendritic, and synaptic development, programmed cell death, and myelination.

In neurulation, primitive cells destined to become neurons originate close to the neuroepithelium of the neural tube. These cells begin rapidly replicating by the fourth week, producing cells that differentiate into bipolar neuroblasts. Some radial glia appear early and serve as scaffolding for

Table 17-1 Major Recognized Causes of Neurodevelopmental Defects of the Nervous System

Genetic Mutations
Mutations primarily affecting gray matter (neurons)
Tay-Sachs disease
Mutations primarily affecting white matter (myelin and their cells of origin)
Adrenoleukodystrophy
Krabbe disease
Unbalanced chromosomes (from duplications or deletions)
Down syndrome
Fragile X syndrome
Toxins
Alcohol
Organic mercury
Lead
Teratogenic Drugs
Anticonvulsants (phenytoin, carbamazepine, and valproic acid)
Thalidomide
Congenital Infections
Rubella
Cytomegalovirus
Toxoplasmosis
Syphilis
Metabolic Diseases
Phenylketonuria
Ionizing Radiation
Defects uncommon unless radiation exposure is very high, which causes fetal death

neurons to migrate to the marginal layer, which will become the gray matter of the cerebral cortex. Ultimately the radial glia divide and become astrocytes. The migration of these postmitotic neurons occurs in a precise orderly manner that is largely completed by the end of the fifth month but does continue at a slow rate until birth. This process appears to produce an excess number of neurons that are subsequently pruned to the appropriate number by a process of programmed cell death called *apoptosis*. Somehow neurons that do not establish correct neuronal connections by late pregnancy are triggered to die. Apoptosis does not elicit inflammation or gliosis, so there is no histologic evidence of their premature death.

Few fetal genes that control this intricate process have been characterized. Homeobox genes comprise a family of genes that encode DNA-binding proteins that regulate gene expression and control various aspects of morphogenesis and cell differentiation. Mutations in homeobox genes often produce malformations in the brain and other organs.

Many terms describe abnormal brain tissue. The term dysplasia refers to abnormal cellular organization resulting in structural and functional consequences. Dysplasias may be localized (such as a hemangioma) or generalized, affecting a variety of structures from widespread distribution of the tissue defect. Heterotopias are portions of an organ displaced to an abnormal site within the same organ of origin, such as nodules of gray matter located in deep white matter due to incomplete neuronal migration. A hamartoma is a portion of tissue at the proper site but is architecturally disorganized, such as a focus of abnormal cortical lamination due to disorganization of pyramidal neurons. Malformation refers to a structural defect arising from a localized error in morphogenesis and may contain one or more of the features described above. Deformation occurs when normally formed tissue is secondarily damaged.

Anencephaly

Introduction

Anencephaly is an abnormality of neurulation that occurs because of failure of closure of the anterior end of the neural tube. The timing of the insult therefore occurs around week 4 of gestation.

Pathophysiology

The causes are unknown. The incidence of anencephaly in the United States is 1/1,000 live births. Failure of anterior neuropore closure results in failure of development of the forebrain and calvarium.

Table 17-2 Milestones in Pre- and Perinatal Development

Time Period of Gestation	Major Developmental Event
Week(s)	
3	Neural tube invaginates
4	Anterior, then posterior ends of neural tube close Brain and head represent 50% of total body length Rapid neuronal division into bipolar neuroblasts at rates up to 250,000 divisions/min Radial glia appear and migration begins
5	Lens placodes of eye develop Forebrain, midbrain, and hindbrain become evident Neuronal migration largely complete Dorsal and ventral horns of spinal cord appear Peripheral nerves appear
6–8	Migration of neurons Ears develop Limbs develop All major organs under development
9–12	Gross brain structure established Glial development and migration appears Very rapid growth of axons and synapses Muscle contractions begin
13–20	Rapid brain growth Central nervous system (CNS) myelination begins α-fetoprotein elevates in amniotic fluid and maternal serum if there is failure of proper neural tube closure
21–40	Primary cerebral fissures appear followed by secondary cerebral sulci Myelination continues Synaptic development continues Neuronal pruning of excess neurons by programmed apoptosis
Birth	Head is 25% of total body length Peripheral nerve myelination almost complete but CNS myelination continues through age 2 years Cry vigorous, sucks and swallows liquids, yawns Suck, root, grasp, and Moro reflex present Head control present Visual and auditory responses elicitable
Months	
2–5	Rapid brain growth continues with head circumference growing at 2 cm/month in first 3 mo and 1 cm/mo during months 4–6 Neurons develop more complex dendrites and synapses Oligodendrocytes and astrocytes in matrix zones continue to divide and migrate to about 6 months Voluntary or social smile appears Head control improves Eye contact increases Turns to sounds
6–11	Rolls over, crawls, begins sitting Babbles, recognizes parents, says “Ma Ma” Head circumference grows at $^1/_2$ cm/mo Moro response and grasp reflex disappear
12	Neuronal dendrites continue growth but head circumference growth slows to $^1/_4$ cm/mo Walks with hand held Uses pincer grip of thumb and forefinger Single words appear Babinski sign disappears

(Table continues)

Table 17-2 ***(Continued)***

Time Period	Major Developmental Event
Months	
15	Walks independently Follows simple commands
18	Runs stiffly Knows about 10 words, identifies pictures Feeds self
24	Runs well, climbs stairs one step at time, opens doors Puts 3 words together (subject, verb, object) Tells of immediate experiences

Major Clinical Features

The most common phenotype has a lack of the cerebral cortex and variable loss of the basal ganglia and upper midbrain, leaving in its place a small hemorrhagic, fibrotic mass of degenerating glia and neurons. The frontal, parietal, and occipital bones are absent, leaving an open calvarium above the eyes.

Major Laboratory Findings

Polyhydramnios (excess amniotic fluid) is a frequent feature. Sonograms are abnormal and demonstrate the malformed head. There is marked elevation of serum and amniotic α-fetoprotein, which is synthesized by the fetal liver, circulates in fetal blood, and is excreted in fetal urine into the amniotic fluid. It is then swallowed and digested by the fetal GI tract. Thus, amniotic fluid and maternal blood normally contain little α-fetoprotein. The protein is elevated in fetal conditions such as open neural tube malformations, abnormalities in the upper GI tract, multiple fetuses, and fetal death. The optimal time to test amniotic fluid for α-fetoprotein is during weeks 14 to 16 gestation, while maternal serum testing occurs at 16 to 18 weeks; both are nearly 100% elevated in anencephaly.

Principles of Management and Prognosis

About three-quarters of affected infants are dead at delivery and the others die in the neonatal period. However, living infants often make sucking and chewing movements and have simple limb movements demonstrating that lower brainstem, spinal cord, and motor neurons are functioning.

Chiari Type I and II Malformations

Introduction

Chiari type I and II malformations are dysplasias of the brainstem, cerebellum, and spinal cord. The etiology is unknown, but there is suspicion of a homeobox gene abnormality. Patients with Chiari type I malformation often have a variable amount of downward displacement of the cerebellar tonsils, which is often found incidentally by neuroimaging. Some individuals develop clinical signs at adolescence when they develop headaches from progressing hydrocephalus, limb spasticity, cerebellar ataxia, and lower cranial nerve dysfunction.

Pathophysiology

The key anatomic features of Chiari II malformation consist of (1) downward displacement and extension of the cerebellar vermis through the foramen magnum and into the cervical canal and (2) downward displacement of the ventral medulla and the inferior fourth ventricle into the cervical canal (Figure 17-1a). In addition, the following associated features frequently occur: (1) elongation of the upper medulla and pons, (2) narrowing of the aqueduct of Sylvius, (3) fibrosis of the cerebellar CSF exits of the fourth ventricle (foramens of Luschka and Magendie), and (4) hydrocephalus

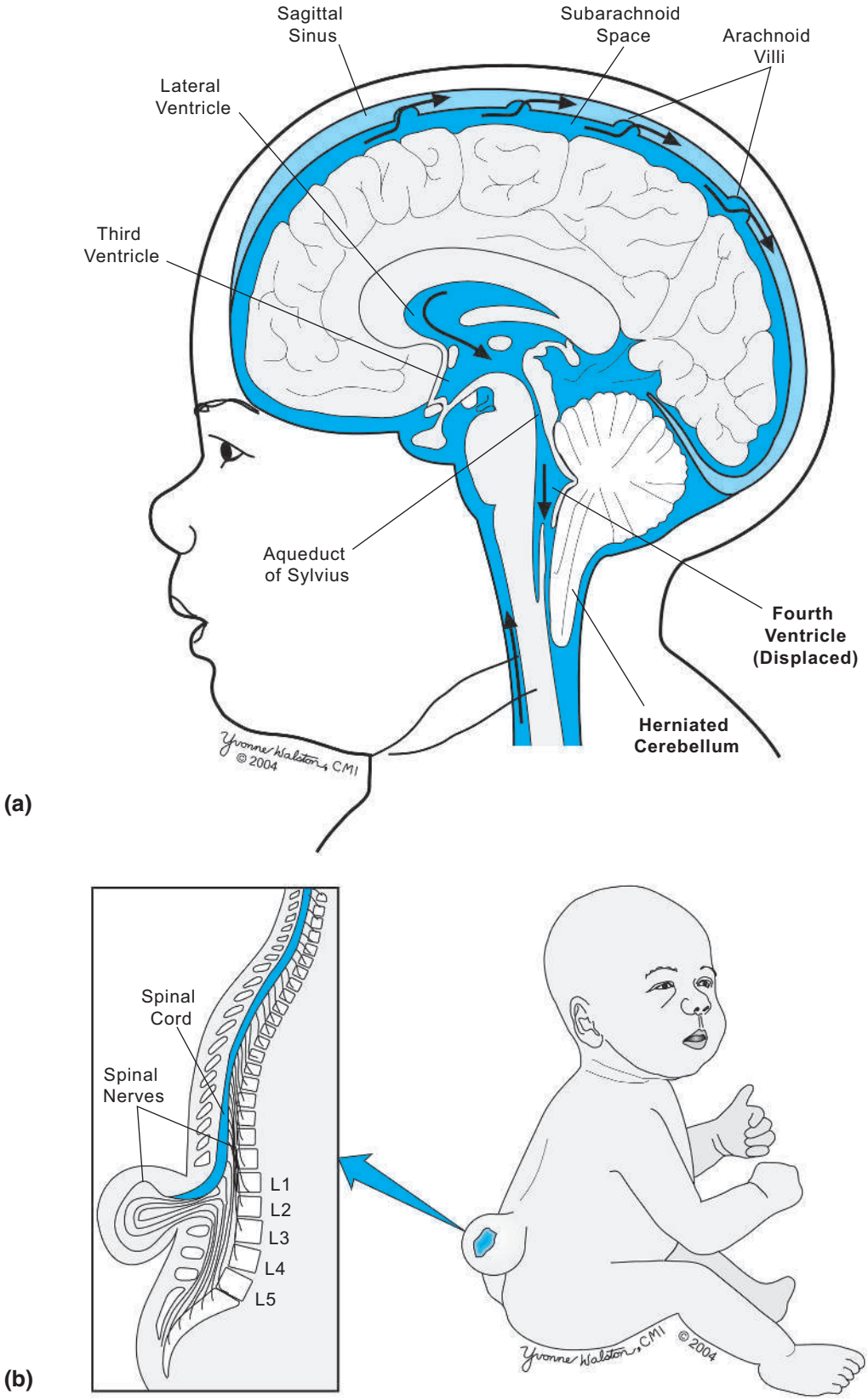

Figure 17-1 Chiari II malformation. (a) Cerebellar and medullary downward displacement. (b) Meningomyelocoele.

secondary to features 2 and 3, and (5) an associated meningomyelocoele in the lumbosacral area. In a meningomyelocoele, failure of the lower vertebral arches to close causes extrusion of the dura, arachnoid and cauda equina, or spinal cord into a cystic swelling that protrudes the skin above the lower back (Figure 17-1b).

Major Clinical Features

The typical child with Chiari type II malformation has progressive hydrocephalus, variable cerebellar ataxia, and lower CN VI though XII dysfunction, with horizontal diplopia, facial weakness, deafness, sternomastoid muscle weakness and head lag, laryngeal stridor, and tongue atrophy. There is variable spastic paraparesis in the arms from secondary cervical stenosis and cervical myelopathy. The meningomyelocoele causes variable paralysis and atrophy of lower-leg and buttock muscles, loss of bowel and bladder control, and lumbar kyphosis. Cysts may develop in the cervical spinal cord, producing syringomyelia with variable loss of sensation (especially pain and temperature) and atrophy of arm muscles.

Major Laboratory Findings

The diagnosis of Chiari II is confirmed in infants born with a meningomyelocoele by MRI, demonstrating the anatomic abnormalities, including protrusion of the cerebellar vermis below the foramen magnum.

Principles of Management and Prognosis

Treatment of infants with type II defects usually involves placement of a ventriculoperitoneal shunt to relieve the increased ventricular CSF pressure from obstructive hydrocephalus and creating a new pathway for exit of ventricular CSF. Depending upon the extent of the lumbosacral nerve damage as the child grows older, bracing may be needed for walking and surgical placement of rods along the lower vertebral bodies for stability to correct the secondary kyphosis that develops. Urinary tract infections are common and secondary kidney problems may develop. While many children with Chiari II malformation have mental retardation, many do not and grow to adults who live normal productive lives. Most children with Chiari I malformation have normal intelligence.

The incidence of both neural tube defects such as anencephaly and Chiari malformations have been greatly reduced by the use of supplemental folate, best administered before conception.

Phenylketonuria (PKU; Phenylalanine Hydroxylase [PAH] Deficiency)

Introduction

Metabolic disorders include derangements in metabolism of amino and organic acids. This includes storage diseases, mitochondrial enzyme defects, and leukodystrophies. These infants usually appear normal at birth but subsequently develop cerebral abnormalities. PKU is the most-common disorder of amino acid metabolism and has an incidence in the United States of 1/14,000 births. PAH deficiency is an autosomal recessive disorder that results in intolerance to the dietary intake of the essential amino acid phenylalanine and produces PKU children with profound and irreversible mental retardation when not treated. PKU is caused by mutations in the *PAH* gene on chromosome 12q23.2. Some mutations allow for partial PAH enzyme function and produce milder forms of the disease.

Pathophysiology

Phenylalanine is metabolized primarily in the liver by hydroxylation via PAH to tyrosine. Mutations of the PAH enzyme cause abnormal elevations in plasma phenylalanine and low tyrosine levels. Normal plasma phenylalanine levels are <120 μmol/L; affected infants are born with normal levels unless the mother has PKU not controlled by diet. After birth, dietary exposure occurs with consumption of either mother's or cow's milk that is rich in phenylalanine and cannot be metabolized to tyrosine. When plasma phenylalanine levels rise above 1,000 μmol/L, damage to the developing CNS occurs. Up to 1 g/d of excess phenylalanine and phenylpyruvic acid is then excreted in urine.

Studies suggest that elevated brain-free phenylalanine and decreased levels of large neutral amino acids (tyrosine and methionine) cause

decreased protein synthesis, increased myelin turnover, and abnormalities in dopamine and norepinephrine neurotransmitter systems. The cerebral cortex that was histologically normal at birth develops abnormalities of myelination, dendritic growth, and synaptic development—i.e., systems that normally continue to mature after birth are affected. In occasional untreated infants, degeneration of established white matter may develop.

Major Clinical Features

Clinically, infants are normal at birth. Over the first year of life, they develop eczematous skin rashes, progressive mental retardation, microcephaly, seizures, and behavioral problems. Hypopigmentation of hair, skin, and iris occurs due to inhibition of tyrosinase and lack of melanin production. Excretion of excessive phenylalanine and its metabolites creates a musty body odor. If PKU is not treated early, the mental retardation is irreversible. Untreated older children may develop spasticity, hyperactive reflexes, and paraplegia. There is increasing evidence that affected infants treated with careful phenylalanine-deficient diets grow to adulthood with an IQ in the broad range of normal. However, subtle cognitive deficits are present. Children experience delayed acquisition of speech, have more behavioral problems, and have some impairment of executive function on neuropsychologic tests. Affected siblings have a lower IQ than those unaffected. Adults who go on a regular diet also may develop mild spasticity and subtle cognitive deficits.

Major Laboratory Findings

The diagnosis is made by newborn screening in virtually 100% of cases, based upon the detection of hyperphenylalaninemia (levels >1,000 μmol/L) using the Guthrie (microbial assay) test on a blood spot obtain from a heel prick obtained several days after feeding begins. The Guthrie screening test usually is confirmed by more specific methods such tandem mass spectrometry. Molecular genetic testing of the *PAH* gene exists but is difficult and expensive since many possible mutation sites exist.

Neuroimaging is normal at birth and later detects irreversible abnormalities mainly in white matter. Histologic changes in untreated cases include hypomyelination or demyelination of white matter, gliosis, and widespread neuronal loss with gross microcephaly.

Principles of Management and Prognosis

The goal of treatment is normalization of plasma concentrations of phenylalanine and tyrosine and the prevention of cognitive disorders. A diet restricted in phenylalanine should be instituted as soon as possible and continued at least into adolescence, and in severe cases for life. A phenylalanine-free medical formula with supplemental tetrahydrobiopterine is needed along with protein restriction, as protein restriction only is insufficient to provide sufficient nutrition and maintain plasma phenylalanine levels <300 μmol/L (5 mg/dL). How high plasma phenylalanine levels can rise in adulthood before cognitive impairment occurs is unclear. However, noncompliance with dietary restrictions and markedly elevated plasma phenylalanine levels can result in decreased cognitive functioning and white matter abnormalities detectable on MRI. Plasma phenylalanine levels must be monitored closely and maintained below 300 μmol/L during pregnancy, as high maternal phenylalanine levels can produce fetal abnormalities.

Tay-Sachs Disease (Hexosaminidase A Deficiency)

Introduction

Tay-Sachs disease is the classic example of a lipid-storage disease and of a genetic disease that primarily affects gray matter (neurons of the brain and retina). Clinicians often divide degenerative diseases in infants and children into those primarily affecting gray or white matter (Table 17-3).

Tay-Sachs disease is a fatal autosomal recessive infantile disease due to severe deficiency of β-hexosaminidase A enzyme, resulting in abnormal accumulation of glycosphingolipid GM2 gangliosides within neurons, leading ultimately to neuronal death. Although cases have been reported in all ethnic groups, the incidence is markedly higher in Jewish communities of Central and Eastern European descent (Ashkenazi Jews). Before current genetic testing, the incidence of Tay-Sachs disease in this population was 1/3,600 births. The

Table 17-3 **Clinical Features of Diseases Affecting Primarily Gray and White Matter**

Gray Matter (Neurons of Brain and Retina)	White Matter (Myelin and Axons)
Loss of previously attained intellectual skills	Spasticity
	Sensory abnormalities
Seizures	Ataxia and incoordination
Aphasia	Visual field defects
Loss of visual acuity	Visual loss
Memory loss	
Variable muscle atrophy from loss of anterior horn neurons	

incidence in other populations is at least 10-fold lower.

Pathophysiology

Hexosaminidase A and B are two catabolic enzymes that hydrolyze gangliosides with terminal β-*N*-acetylgalactosamine residues. In Tay-Sachs disease, there is a mutation in the hexosaminidase-α subunit such that the enzymatic activity of hexosaminidase B is normal but is nearly absent in hexosaminidase A. As a consequence, the ganglioside GM2 cannot be catabolized and accumulates within the cytoplasm of neurons, eventually causing the neuron's death. In the retina, the fovea lacks ganglion cell bodies. Thus accumulation of whitish GM2 gangliosides in ganglion neurons surrounding the fovea is seen with an ophthalmoscope as a "cherry red spot."

Pathologically, there is a large brain containing excessive neuronal glycolipids (up to 12% of the brain dry weight contains GM2 gangliosides). There is widespread loss of neurons, with reactive gliosis. All remaining neurons are distended with glycolipid.

Major Clinical Features

Affected infants appear normal at birth. By 3 months, infants develop mild weakness, myoclonic jerks, and startle responses to sudden noises. By 9 months, the infant fails to achieve milestones and is losing those already acquired. Weakness is more pronounced. There is diminished visual attentiveness from loss of acuity, and a "cherry red spot" is seen in the retina on fundoscopy. By 12 months, voluntary limb movements are minimal, vision is lost, and partial complex and absence seizures develop. By year 2, the infant has decerebrate posturing, marked seizures, swallowing difficulties, and becomes almost vegetative. Death from bronchopneumonia occurs between ages 2 and 4 years.

Major Laboratory Findings

The diagnosis is established by demonstration of deficient hexosaminidase A enzymatic activity in the serum or WBCs of a symptomatic individual in the presence of normal activity of the hexosaminidase B isoenzyme. Mutation analysis of the *HEXA* gene on chromosome 15q23-q24 can be done, but is less sensitive than the enzymatic assay because current assays do not detect all 90 known mutations.

Neuroimaging shows an enlarged head from gliosis and not hydrocephalus. The EEG is abnormal early and shows paroxysmal slow waves and spikes.

Principles of Management and Prognosis

No treatment currently exists to replace the missing hexosaminidase A enzyme, and the disease relentlessly progresses to death. The goal of management is to provide supportive care, give adequate nutrition and hydration, minimize respiratory infections, and control seizures with anticonvulsants.

Since asymptomatic, heterozygote carriers can be detected by a simple, inexpensive, and sensitive serum hexosaminidase A enzyme assay, genetic screening as well as prenatal genetic tests are frequently done. Currently, Jews of Ashkenazi extractions are often tested when reaching adulthood. Prenatal testing is available when both parents are heterozygous or the mother is heterozygous and the father is unknown. The hexosaminidase A assay can be performed upon a chorionic villus sample at 10 to 12 weeks' gestation or by amniocentesis at 16 to 18 weeks' gestation.

Down Syndrome

Introduction

Chromosomal abnormalities occur when there are too many copies, too few copies, or abnormal arrangements (duplications or deletions) of normal genes. At least 0.5% of all live births and 50% of spontaneously aborted fetuses in the first trimester are the consequence of chromosomal imbalances. The human genome contains approximately 6×10^9 base pairs of DNA, and is 2 m long if uncoiled. Each somatic cell has 22 pairs of homologous chromosomes that are identical in morphology and constituent gene loci plus 1 pair of sex chromosomes. Malformations are likely to develop if this genetic arrangement is significantly altered.

Most chromosomal disorders involving autosomal chromosomes are associated with multiple congenital abnormalities. Many of these individuals have in common some degree of intrauterine and postnatal microcephaly, mental retardation, seizures, and assorted ocular, gastrointestinal, and skin abnormalities. Only 3 autosomal trisomies (13, 18, and 21) survive to term and only trisomy 21 or Down syndrome survives past one year. Some patients with various chromosome deletions express only mild signs.

Down syndrome occurs around the world and has a prevalence of 90/100,000 live births and increases dramatically with maternal age >35 years.

Pathophysiology

About 95% of individuals with Down syndrome have trisomy 21 or three copies of chromosome 21 from nondisjunction mainly during gamete formation in the mother. The risk of this maternal abnormality increases with age. Of these cases 5% have translocations where all or part of chromosome 21 is attached to another chromosome, usually 14. It is still unknown how the presence of additional chromosome 21 genes causes this complex but easily recognized syndrome. Chromosome 21 is the shortest chromosome, and genetic mapping of the human chromosome suggests it contains only 225 genes. Clinical features are identical in children with trisomy or translocation.

Brain size and weight are normal at birth, but there is foreshortening of the anterior–posterior head diameter, flattening of the occiput, and narrowing of the superior temporal gyrus. The primary gyri are wider than normal and secondary gyri are narrower. The cerebellum and brainstem are smaller than normal. Reduced numbers of neurons in the cortex and hypomyelination are present and continue in subsequent growth. As the child grows older, there is significant reduction in linear growth and brain growth. Most adults have short stature and mild microcephaly.

Adults demonstrate basal ganglia calcifications and after the age of 30 years develop senile plaques and neurofibrillary tangles similar to those seen in Alzheimer's disease. By age 50 years, there is considerable loss of cortical neurons and brain atrophy.

Major Clinical Features

Newborns have hypotonia, hyperextensible joints, excess skin on the back of the neck, flat facial profiles, slanted palpebral fissures, overfolded helices, protruding tongues, short fifth fingers, and single palmar creases (Figure 17-2). Congenital heart disease is present in 50%. Moderate mental retardation becomes apparent as the child grows. In addition, the child may develop strabismus, nystagmus, small genitalia, and pectus excavatum. Some children have immunoglobulin imbalance and a susceptibility to respiratory infections while some, especially older children, develop hypothyroidism. Most males are infertile. In adulthood after the age of 30 years, a progressive dementia that has features of Alzheimer's disease often worsens the existing mental retardation.

Major Laboratory Findings

Neuroimaging in childhood may demonstrate hypomyelination for age. In adults, basal ganglia calcifications are seen in 50% of cases; brain atrophy is seen in older adults.

Karyotyping performed on blood lymphocytes or skin fibroblasts establishes the diagnosis and determines whether the cause is trisomy 21 or translocation. Finding a translocation means that subsequent children of the mother or affected individual carry a 50% risk of having Down syndrome.

Principles of Management and Prognosis

The goal of management is to prevent or minimize recognized malformations of the heart, thyroid,

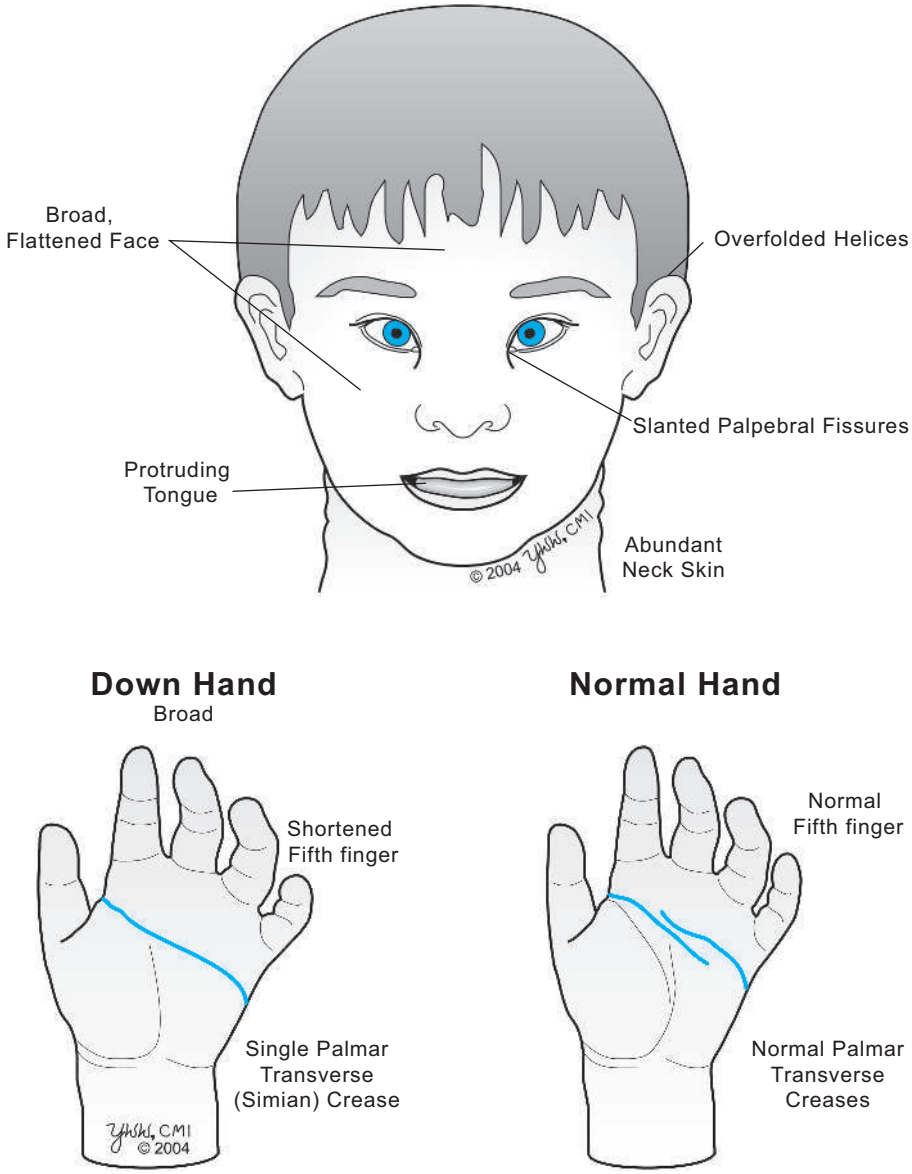

Figure 17-2 *Down syndrome (Trisomy 21) features.*

and GI tract and maximize the potential of the individual. Infants should have careful cardiac, hearing, and thyroid evaluations. Respiratory and ear infections should be treated aggressively. Older children may require special school supports but should attend regular elementary and high schools. Repeat testing in children and adults for problems of thyroid function, vision, hearing, and cardiac problems should be done. The mean age of survival at birth is 50 years.

RECOMMENDED READING

Fenichel GM. *Clinical Pediatric Neurology: A Sign and Symptom Approach.* 4th ed. Philadelphia: W.B. Saunders Company; 2001. *(This and other pediatric neurology textbooks cover the many disorders of the developing nervous system in detail.)*

Hoffman HJ, Hendrick EB, Humphreys RP. Manifestations and management of Arnold-Chiari malformations in patients with myelomeningo-

cele. *Childs Brain* 1975;1:255–259. *(Old but good review.)*

Medical Research Council Working Party on Phenylketonuria. Phenylketonuria due to phenylalanine hydroxylase deficiency: an unfolding story. *BMJ* 1993;306:115–119. *(Excellent review of subtle cognitive and neurologic changes that develop in children treated with strict phenylalanine diets.)*

Ryan S, Scriver CR. Phenylalanine hydroxylase deficiency. Available at: http://www.geneclinics.org. Accessed August 26, 2002. *(This Web site has outstanding, constantly updated reviews on many genetic diseases.)*